



Intrapelvic entrapment of sacral nerve roots by abnormal bundles of the piriformis muscle: description of an extra-spinal cause of sciatica and pudendal neuralgia

Corey Sermer ¹, Adrienne L.K. Li¹, Gustavo L. Fernandes^{2,3},
Augusta M. Ribeiro², Giancarlo Polesello³, Denise Tokechi⁴,
Laura Cancelliere¹ and Nucelio Lemos ^{1,2*}

¹Mount Sinai Hospital, 700 University Avenue, Room 8-917, Toronto, ON M5S 1Z5, Canada,

²Department of Gynecology, Federal University of São Paulo. Rua Napoleão de Barros, 608, São Paulo, SP, Brazil,

³Department of Gynecology, Faculdade de Ciências Médicas da Santa Casa de São Paulo. Rua Doutor Cesário Mota Júnior, 42, São Paulo, SP, Brazil, and

⁴Department of Radiology, Hospital Sírio-Libanês, Rua Dona Adma Jafet, 91, São Paulo, SP, Brazil. .

*Correspondence to: N. Lemos. E-mail: nucelio.lemos@wchospital.ca

Submitted 4 October 2020; Revised 21 March 2021

ABSTRACT

Piriformis syndrome is a well-known extra-spinal cause of sciatica characterized by the entrapment of the sciatic nerve by variant bundles of the piriformis muscles in the deep gluteal space. In this case series, we describe the entrapment of intrapelvic portions of the sacral nerve roots by a variant bundle of the piriformis muscle originating medially to the sacral foramina, the surgical technique for the laparoscopic treatment of this condition, and the outcomes of the first eight cases treated with this technique. Five female and three male patients presenting with sciatica, pudendal pain and lower urinary tract symptoms underwent a laparoscopic exploration of the intrapelvic portion of the sacral nerve roots and transection of the abnormal piriformis bundle. Surgical technique is demonstrated in the [Supplementary Video](#). Clinical success was achieved in seven of the eight patients, with a reduction of pain numeric rating scale from 8.5 (± 1.2 ; 7–10) pre-operatively to 2.1 (± 2.6 ; 0–7), 1-year following surgery. In conclusion, entrapment of intrapelvic portions of the sacral nerve roots by variant bundles of the piriformis originating medially to the sacral foramina are an extraspinal cause of sciatica, which can be treated through a laparoscopic approach.

INTRODUCTION

Sciatica is relatively common condition with a lifetime incidence of 13–40% [1]. While the majority of cases are usually attributed to intervertebral etiologies such as disk herniations or degenerative disc disease, piriformis syndrome is an extra-spinal cause that can be difficult to diagnose and treat [2–4].

Anatomical variations and abnormal bundles of the piriformis have long been known to cause entrapment of the sciatic nerve at the deep gluteal space. The classic publication of Beaton and Anson [5] in 1937 reported the prevalences

of five anatomical variations that could potentially entrap the sciatic nerve in the deep gluteal space. Since then, several other anatomical variations of the piriformis muscle have been associated with sciatica [3, 6–11].

The development of the Laparoscopic Neuronavigation (LANN) technique [12] allows for access to the intrapelvic portion of the lumbosacral plexus, which has been overlooked by pelvic surgeons due to lack of awareness and by orthopedic and neurosurgeons due to the lack of surgical training to access these deeper portions of the pelvis.

Generally, the sciatic nerve is formed by fibers originating from nerve roots L4 to S3 that merge in the pelvis on the ventral surface of the piriformis muscle, leaving to the deep gluteal space through the major sciatic foramen (Fig. 1). Through the LANN technique, we have identified abnormal bundles of the piriformis muscle originating medially to the sacral foramina and entrapping the pelvic portions of the sacral plexus (Fig. 1). The objective of this report is to demonstrate the surgical technique for treating such entrapments of the intrapelvic portions of the sacral nerve roots and review our initial results with this technique.

METHODS

A retrospective analysis of the first eight cases of piriformis syndrome undergoing laparoscopic surgery between March 2012 and May 2018 in a tertiary referral center in Sao Paulo, Brazil, was performed. Prior to surgery, informed consent for the proposed procedure was obtained from each patient, as well as authorization for the use of case data and images for research and educational purposes.

Research Ethics Board (REB) approval was obtained from the Federal University of São Paulo (REB # 3.272.139).

Patient information, including demographics, history and physical exam findings, urodynamic studies, imaging results, and any prior interventions were extracted from patient charts. Additionally, post-operative outcomes, including ongoing symptoms (or lack thereof), complications, or further interventions were also extracted from patient charts in a similar manner.

The primary outcome was pain as assessed by the numeric rating scale (NRS) on the last pre-operative consultation compared to 1-year post-operative follow-up. A paired student's *t*-test was performed to determine significant differences between pre- and post-operative scores, with $P < 0.05$ considered statistically significant. Statistical analyses were performed using GraphPad Prism Version 6.0c (San Diego, CA, USA).

Diagnostic workup

All patients on this series were assessed by the senior author (N.L.), who is a gynecologist with fellowship training in Neuropelvelogy and the LANN technique. Seven

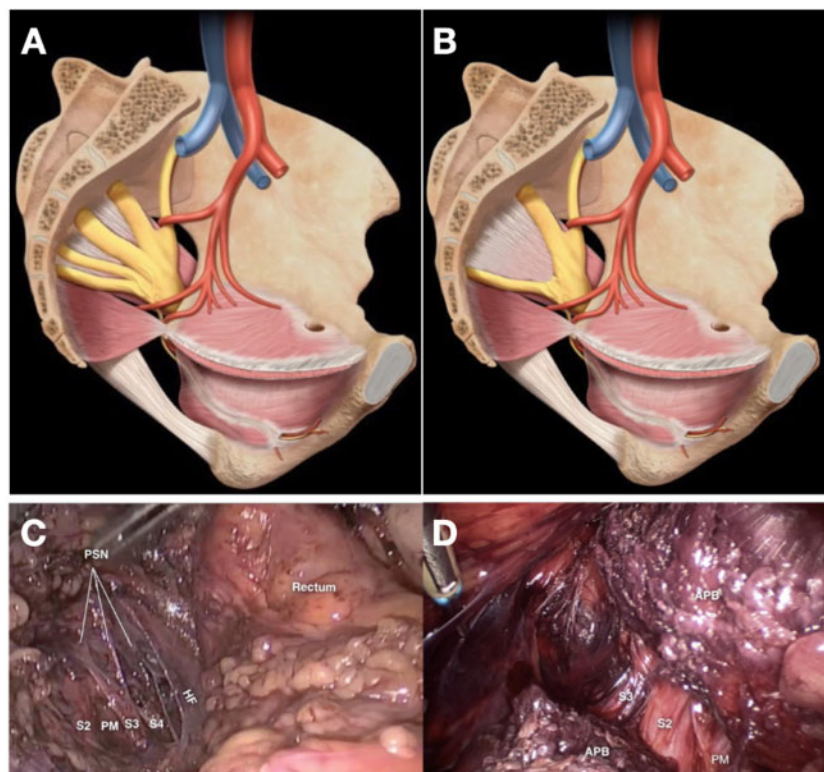


Fig. 1. Left (A and C)—normal intrapelvic sacral plexus, with the nerve roots (S2, S3 and S4) lying on the ventral aspect of the piriformis muscle. Right (B)—variant anatomy, with the nerve roots (S2 and S3) entrapped between the aberrant piriformis bundle (APB) and the normal piriformis muscle (PM) bundles. (D) Intraoperative view after transection of the APB on a LANN detrapment procedure. HF, hypogastric fascia; PSN, pelvic splanchnic nerves.

patients were also assessed by a hip surgeon and a spinal surgeon to rule out other causes of sciatica and/or radicular pain.

The diagnostic workup evolved with the understanding of the condition. History included a detailed inventory of pain characteristics and associated symptoms. Physical exam included a pelvic exam and detailed neurological examination, including a piriformis stretch maneuver, where the sensitivity of the sacral nerve dermatomes is tested with the piriformis muscle in a normal resting state and compared to the sensitivity with the piriformis under stretch (Fig. 2).

Pelvic magnetic resonance imaging (MRI) was used to confirm the presence of an abnormal piriformis muscle bundle and, in some cases, magnetic resonance (MR) tractography confirmed a conduction alteration on the intrapiriformis segment of the nerve root (Fig. 3). This analysis was done retrospectively. Transforaminal diagnostic blocks were used to confirm the diagnosis.

Surgical technique

Laparoscopy was performed under general anesthesia. A 10 mm camera port was placed through the umbilicus and three ancillary 5 mm ports were placed on the lower left quadrant, suprapubically and on the lower right quadrant. The presacral space was developed through a peritoneal incision at the level of the sacral promontory; the retrorectal

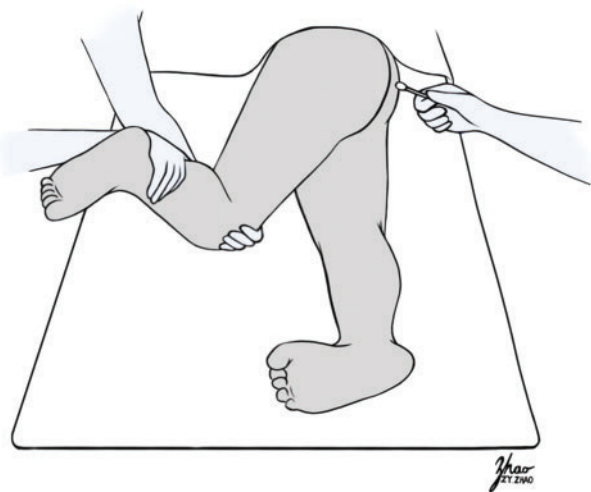


Fig. 2. The piriformis stretch test is performed by two examiners with the patient in lateral decubitus position. An initial neurological exam is performed on the sacral dermatomes. The second examiner then performs a piriformis stretch maneuver by flexing the hip to 45–90°, adducting the hip past the midline and performing internal rotation of the hip. This maneuver should trigger/exacerbate the patient symptoms and/or exacerbate the asymmetry in sensation on the affected sacral dermatomes.

space was developed and the hypogastric nerve identified. The presacral fascia was pierced laterally to the hypogastric nerve and the presacral space was developed. The hypogastric fascia was then opened, revealing an abnormal piriformis bundle covering the expected nerve roots. The abnormal bundle was then transected, layer by layer, with special care taken to avoid any damage to the underlying sacral nerve roots. The abnormal muscle was then mobilized under the internal iliac vessels and hip rotation and adduction was used to retract the muscle toward the deep gluteal space.

Video footage of one of the cases was edited to demonstrate the laparoscopic management of an intrapelvic entrapment of sacral nerve roots by the piriformis muscle (see [Supplementary Video](#), Supplementary Digital Content 1, which demonstrates the surgical technique).

To avoid fibrosis formation and subsequent recurrence of symptoms, patients were taught sciatic sliding and plexus mobilization exercises on post-operative day 10. Patients were instructed to perform the exercises twice daily, for 10 min, during the 6 months following surgery.

RESULTS

Our initial experience thus far comprises eight patients, five females (62.5%) and three males (37.5%). The average age was 46.5 (± 14.0 ; 35–69) years. The average time from symptom onset to diagnosis was 5.1 (± 5.0 ; 0.5–15) years. The average surgical time was 113.3 (± 30.0 ; 66–161) min. The average follow-up time was 27.5 (± 12.7 ; 15.6–55.7) months.

Table I summarizes the diagnostic workup findings of all eight patients. The first patient in this series was not assessed by hip/spinal surgeons because the diagnostic hypothesis for her surgery was of pararectal endometriosis entrapping the S2 and S3 nerve roots and the diagnosis of piriformis entrapment was intraoperative.

Mean pre-operative NRS score was 8.5 (± 1.2 ; 7–10); post-operatively, this decreased to 2.1 (± 2.6 ; 0–7) ($P < 0.05$), 1 year after surgery (**Table II**). Clinical success, defined as a $\geq 50\%$ decrease in NRS scores, was achieved in 7/8 (87.5%) of patients (**Table II**). Notably, the only patient that did not achieve clinical success had adhesions of the retracted piriformis muscle bundle in the deep gluteal space and as such required a transgluteal endoscopic approach. At final follow-up, at a mean 27.5 (± 12.7 ; 15.6–55.7) months, the NRS score was 2.3 (± 2.7 ; 0–7), which remained significantly different compared to pre-operative assessment ($P < 0.05$).

There were no intraoperative complications. Post-operatively, five patients (62.5%) experienced post-decompression neuralgia for an average of 5.4 (± 4.3 ; 1–12)

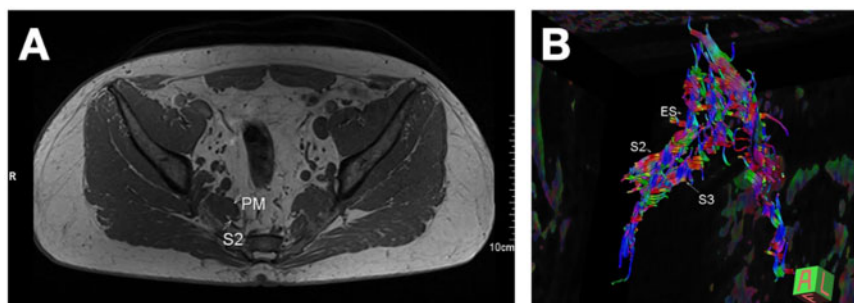


Fig. 3. (A) Representative MR neurography showing the S2 nerve root crossing between the piriformis muscle (PM) fibers. (B) MR tractography imaging showing the narrowing of the nerve tracts at the entrapment site (ES); notice that the variability of colors is reduced, as a result of hydrogen ions following the path of least resistance through the entrapment.

months. Only one patient (12.5%) experienced a loss of muscle strength; however, this resolved after 1 month. Additionally, one patient required caudal nerve blocks with cortisone injections with pelvic floor physiotherapy for ongoing symptom relief. Furthermore, one patient developed hyponatremia secondary to duloxetine use; however, this was unrelated to the surgical procedure.

DISCUSSION

This study reports the outcomes of eight patients with piriformis syndrome undergoing laparoscopic detrapment of the intrapelvic portions sacral nerve roots entrapped by variant piriformis muscle bundles originating medially to the sacral foramina. We demonstrated a significant improvement in NRS scores following surgery, defined as clinical success, in seven of eight patients after 1 year.

The differential diagnosis of sciatica is vast and has traditionally considered various sites of the entrapment at the spine, including the intervertebral foramen, and along the course of the sciatic nerve [1, 13]. However, as part of the lumbosacral plexus, the sciatic nerve also traverses the pelvis, and this anatomic location has been under-recognized for possible pathologies such as vascular entrapment [14], endometriosis [15] and, as reported here, variant piriformis muscle anatomy.

The sciatic nerve typically emerges from the pelvis over the ventral surface of the piriformis muscle. However, the nerve may divide into its tibial and common peroneal portions within the pelvis, or the muscle may split into two separate heads [5]. In people with these anatomic variations, contraction of the piriformis muscle can compress the nerve, leading to inflammation and neuralgia [1, 13]. Our report describes intrapelvic entrapments of the sacral nerve roots by a previously described anatomic variation of the intrapelvic portion of piriformis muscle which was thought to be physiologic and unknown to cause nerve entrapments [16]. These entrapments produce symptoms

related to the affected nerve roots dermatomes and myotomes, such as sciatica, pudendal neuralgia, lower urinary tract symptoms, pelvic pain and anorectal and sexual dysfunction.

Diagnosis, however, needs to be based on a combination of clinical assessment, nerve blocks and image findings, as a variant piriformis muscle bundles can often be found originating medially to sacral foramina in asymptomatic subjects [16]. Here, we propose a diagnostic sequence based on clinical history revealing pain on the S1, S2 and/or S3/S4 dermatomes, with symptoms and/or sensory changes elicited by a piriformis stress test, MRI \pm MR tractography, and a selective, transforaminal nerve block. The accuracy of these diagnostic maneuvers still needs to be assessed, but they provide guidance on patient selection. In three cases in our series, we have added MR tractography to our MRI sequences, in an attempt to explore imaging markers for entrapment; the accuracy of tractography findings still, however, need to be analyzed in an adequately powered and controlled study.

Piriformis syndrome has traditionally been diagnosed and treated with local anesthetic nerve blocks, steroid injections and botulinum toxin injections [17–21]. Lifestyle modifications, physical therapy and neuropathic pain medications are other adjuvant conservative management options [17, 22]. In refractory cases, surgical detrapment can provide symptomatic relief [23–27].

Surgeries to detrap the sciatic nerve in piriformis syndrome include open transgluteal procedures [25, 28] and hip endoscopic surgery [29]. However, these surgeries cannot access the sciatic nerve at its intrapelvic course. This study describes a laparoscopic approach that allows for a minimally invasive, safe and effective way of treating these anatomic variants in symptomatic patients.

Albeit very encouraging, our results are still preliminary, and any further analysis is limited by the small number of cases. Nevertheless, our success rate is higher than other

Table I. Clinical, urodynamic and radiological findings during initial work up

Subject	Age	Sex	Affected nerve roots	Symptoms	Physical exam findings	Urodynamic findings	Imaging
1	36	F	S2–S3 right	Right gluteal pain, right pudendal pain, superficial dyspareunia, medial sciatica (S2 dermatome), urinary frequency and Urgency, discharge. Pain was worse with sitting, improved by moving around. No clear correlation with activity (patient was not an active person).	Hyperesthesia and hyperalgesia on right S2 and S3 dermatomes.	Detrusor overactivity and detrusor-sphincter incoordination. No incontinence.	Variant piriformis bundle originating medially to the S2 and S3 foramina. Tractography not available.
2	60	F	S2 left	Left Pudendal Pain, Left Medial sciatica (S2 dermatome), urinary frequency and urgency. Pain was worse with sitting, improved with walking.	Allodynia on S2 dermatome on the left. Hyperesthesia and Hyperalgesia on S2 on the left upon piriformis stretch maneuver	Detrusor overactivity and detrusor-sphincter incoordination. No incontinence	Variant piriformis bundle originating medially to the S2 foramen. Tractography not available.
3	38	F	S2–S3 bilateral	Bilateral pudendal pain, bilateral medial sciatica, urinary urgency and frequency, superficial dyspareunia, fecal urgency. Pain was worse with sitting and physical activity.	Allodynia on S2 and S3 dermatomes bilaterally. Symptoms triggered by piriformis stretch maneuvers	Detrusor overactivity and detrusor-sphincter incoordination. No incontinence	Variant piriformis bundle originating medially to the S2 and S3 foramina bilaterally. Tractography not available.
4	36	M	S2/S3 on the right	Right-sided medial sciatica, penile pain and numbness, erectile dysfunction, right-sided gluteal pain, urinary urgency, frequency and urge-incontinence.	Allodynia on S2 and S3 dermatomes on the right. Symptoms triggered by piriformis stretch maneuvers.	Detrusor overactivity with incontinence and detrusor-sphincter incoordination.	Variant piriformis bundle originating medially to the S2 and S3 foramina on the right. Tractography not available.
5	60	M	Right S2 and S3	Right-sided gluteal pain, worse on sitting or lying on either side. No urinary, anorectal or pudendal symptoms.	Normal sensation on non-stress exam, allodynia on right S2, S3 dermatomes with piriformis stretch maneuver.	Normal urinary function.	Variant piriformis muscle bundle originating medially to the right S2 and S3 foramina. Piriformis muscle volume was smaller on the right than the left and inflammation was suggested given hypersignal in T2 sequences. Tractography showed a narrowing of tracts and reduced anisotropy on S2 and S3 nerve roots.
6	69	M	Right S1	Lateral (S1) sciatica on the right, increased by physical activity (cycling, running, squatting exercises)	Allodynia on right S1 dermatome. Symptoms triggered by piriformis stretch maneuver.	Normal urinary function.	Variant piriformis muscle bundle originating medially to the right S1 foramen. Tractography showed a signal gap at the intrapiriformis level of the S1 nerve root.

(continued)

Table I. (Continued)

Subject	Age	Sex	Affected nerve roots	Symptoms	Physical exam findings	Urodynamic findings	Imaging
7	38	F	Bilateral S2 and S3	Patient developed pudendal neuralgia after an ischirectal hematoma during delivery. In 6 months with pudendal neuralgia, patient developed bilateral pudendal pain and medial sciatica. Urinary urgency, frequency and dysuria.	Allodynia on S2 and S3 dermatomes bilaterally.	Oversensitivity, stable detrusor, detrusor-sphincter incoordination.	Increased vascularity around the left pudendal nerves and distal aspect of S3 and S4 nerve roots, with altered signal on tractography. Bilateral variant piriformis muscle bundles originating medially to the S3 and S3 foramina.
8	35	F	Right S2 entrapment	Right medial sciatica. No urinary or anorectal symptoms.	Allodynia on right S2 dermatome.	Oversensitivity, stable detrusor, detrusor-sphincter incoordination.	Abnormal piriformis muscle bundle originating medially to the right S2 foramen. Tractography not available.

Table II Summary of patient demographics and surgical outcomes

N = 8	Average \pm SD (range)
Age	46.5 \pm 14.0 (35–69) years
Time from symptom onset to diagnosis	5.1 \pm 5.0 (0.5–15) years
Pre-operative NRS ^a	8.5 \pm 1.2 (7–10)
1-year post-operative NRS ^a	2.1 \pm 2.6 (0–7)
Average surgical time	113.3 \pm 30.0 (66–161) min

aNRS, Numeric Rating Scale.

previously published surgeries for piriformis entrapment [17, 24, 25], which may reflect a less intense entrapment and a slower axonal degeneration process than when the entrapment is caused by tendons in the deep gluteal space; this may also reflect a more specific diagnosis. On the other hand, our findings may have resulted simply from chance and not reflect reality given that our report is not adequately powered.

Nevertheless, recognizing this and other causes of intrapelvic nerve entrapments is key for the differential diagnosis and effective treatment of several conditions, such as pudendal neuralgia, sciatica, chronic pelvic pain, bladder pain syndrome, anorectal dysfunction and many other debilitating disorders.

The study also poses another significant question: given the prevalence of these anatomic variations in the general population, understanding the factors leading to the onset of symptoms might be key for prevention. From our initial impression, symptoms are usually triggered by situations that lead to an alteration of the hip/pelvis biomechanics, such as pregnancy, changes in physical activity pattern or trauma. These hypotheses need to be investigated in larger longitudinal studies.

In conclusion, this case series brings up the hypothesis of intrapelvic entrapment of sacral nerve roots by a variant piriformis bundle that has, until this moment, been considered physiological. We also propose a diagnostic rationale for patient selection that, while still needing to have its accuracy verified, has allowed for good clinical outcomes. MR tractography has also been proposed as a possible additional tool for objectively diagnosing intrapelvic entrapments of the lumbosacral plexus. While these propositions still need further verification, they do pose some directions for future research on extraspinal sciatica.

SUPPLEMENTARY DATA

Supplementary data are available at *Journal of Hip Preservation Surgery* online.

ACKNOWLEDGEMENTS

The authors would like to acknowledge Zi Ying Zhao for providing the medical illustrations in Fig. 2.

CONFLICT OF INTEREST STATEMENT

N.L. received research support and proctorship grants from Medtronic Inc. and speaker honoraria from Promedon Inc. None of these grants are directly related to the current publication. None of the other co-authors have anything to disclose.

REFERENCES

- Stafford MA, Peng P, Hill DA. Sciatica: a review of history, epidemiology, pathogenesis, and the role of epidural steroid injection in management. *Br J Anaesth* 2007; **99**: 461–73.
- Cass SP. Piriformis syndrome: a cause of nondiscogenic sciatica. *Curr Sports Med Rep* 2015; **14**: 41–4.
- Probst D, Stout A, Hunt D. Piriformis syndrome: a narrative review of the anatomy, diagnosis, and treatment. *PM R* 2019; **11**: S54–63.
- Kirschner JS, Foye PM, Cole JL. Piriformis syndrome, diagnosis and treatment. *Muscle Nerve* 2009; **40**: 10–8.
- Beaton L, Anson B. The relation of the sciatic nerve and of its subdivisions to the piriformis muscle. *Anat Rec* 1937; **70**: 1–5.
- Robinson DR. Piriformis syndrome in relation to sciatic pain. *Am J Surg* 1947; **73**: 355–8.
- Pecina M. Contribution to the etiological explanation of the piriformis syndrome. *Acta Anat (Basel)* 1979; **105**: 181–7.
- Natsis K, Totlis T, Konstantinidis GA *et al.* Anatomical variations between the sciatic nerve and the piriformis muscle: a contribution to surgical anatomy in piriformis syndrome. *Surg Radiol Anat* 2014; **36**: 273–80.
- Smoll NR. Variations of the piriformis and sciatic nerve with clinical consequence: a review. *Clin Anat* 2010; **23**: 8–17.
- Bartret AL, Beaulieu CF, Lutz AM. Is it painful to be different? Sciatic nerve anatomical variants on MRI and their relationship to piriformis syndrome. *Eur Radiol* 2018; **28**: 4681–6.
- Windisch G, Braun EM, Anderhuber F. Piriformis muscle: clinical anatomy and consideration of the piriformis syndrome. *Surg Radiol Anat* 2007; **29**: 37–45.
- Possover M, Rhiem , Chiantera , The "Laparoscopic Neuro-Navigation"—LANN: from a functional cartography of the pelvic autonomous neurosystem to a new field of laparoscopic surgery. *Minim Invasive Ther Allied Technol* 2004; **13**: 362–7.
- Jankovic D, Peng P, van Zundert A. Brief review: piriformis syndrome: etiology, diagnosis, and management. *Can J Anaesth* 2013; **60**: 1003–12.
- Kale A, Basol G, Usta T *et al.* Vascular entrapment of both the sciatic and pudendal nerves causing persistent sciatica and pudendal neuralgia. *J Minim Invasive Gynecol* 2019; **26**: 360–1.
- Denton RO, Sherrill JD. Sciatic syndrome due to endometriosis of sciatic nerve. *South Med J* 1955; **48**: 1027–31.
- Russell JM, Kransdorf MJ, Bancroft LW *et al.* Magnetic resonance imaging of the sacral plexus and piriformis muscles. *Skeletal Radiol* 2008; **37**: 709–13.
- Fishman LM, Dombi GW, Michaelsen C *et al.* Piriformis syndrome: diagnosis, treatment, and outcome—a 10-year study. *Arch Phys Med Rehabil* 2002; **83**: 295–301.
- Hanania M, Kitain E. Perisciatic injection of steroid for the treatment of sciatica due to piriformis syndrome. *Reg Anesth Pain Med* 1998; **23**: 223–8.
- Albayrak A, Ozcafer R, Balioglu MB *et al.* Piriformis syndrome: treatment of a rare cause of posterior hip pain with fluoroscopic-guided injection. *Hip Int* 2015; **25**: 172–5.
- Jeong HS, Lee GY, Lee EG *et al.* Long-term assessment of clinical outcomes of ultrasound-guided steroid injections in patients with piriformis syndrome. *Ultrasonography* 2015; **34**: 206–10.
- Masala S, Crusco S, Meschini A *et al.* Piriformis syndrome: long-term follow-up in patients treated with percutaneous injection of anesthetic and corticosteroid under CT guidance. *Cardiovasc Intervent Radiol* 2012; **35**: 375–82.
- Miller TA, White KP, Ross DC. The diagnosis and management of Piriformis Syndrome: myths and facts. *Can J Neurol Sci* 2012; **39**: 577–83.
- Ilizaliturri VM, Arriaga R, Villalobos FE Jr *et al.* Endoscopic release of the piriformis tendon and sciatic nerve exploration. *J Hip Preserv Surg* 2018; **5**: 301–6.
- Indrekvam K, Sudmann E. Piriformis muscle syndrome in 19 patients treated by tenotomy—a 1- to 16-year follow-up study. *Int Orthop* 2002; **26**: 101–3.
- Benson ER, Schutzer SF. Posttraumatic piriformis syndrome: diagnosis and results of operative treatment. *J Bone Joint Surg Am* 1999; **81**: 941–9.
- Lemos N, Possover M. Laparoscopic approach to intrapelvic nerve entrapments. *J Hip Preserv Surg* 2015; **2**: 92–8.
- Possover M. Laparoscopic management of endopelvic etiologies of pudendal pain in 134 consecutive patients. *J Urol* 2009; **181**: 1732–6.
- Filler AG, Haynes J, Jordan SE *et al.* Sciatica of nondisc origin and piriformis syndrome: diagnosis by magnetic resonance neurography and interventional magnetic resonance imaging with outcome study of resulting treatment. *J Neurosurg Spine* 2005; **2**: 99–115.
- Mizuguchi T. Division of the piriformis muscle for the treatment of sciatica. Postlaminectomy syndrome and osteoarthritis of the spine. *Arch Surg* 1976; **111**: 719–22.